



## **Surgical Correction for Spinal Stenosis: an example of seeing that the patient gets the proper care for the condition**

submitted by  
James M. Cox, DC, DACBR  
Fort Wayne, IN  
*on March 12, 2010*

### **HISTORY**

This case shows the marked change in the spine following decompression laminectomy and fusion of the lumbar spine. This female patient had marked bilateral sciatic pain due to spinal stenosis as shown in Figures 1 to 7. The pain was of the intensity that she could not sleep at night nor perform usual activities of daily living.

### **IMAGING (follows)**

### **TREATMENT**

Flexion distraction decompression gave her some early relief, but within two years the pain progressed, and epidural steroid injections were given without relief. A pain control electrical stimulator was implanted into her spinal cord without relief.

With no help from conservative means, the patient sought care at the Cleveland Clinic where images in figures 8 and 9 show the spine post-surgically. It is a remarkable correction of the scoliosis. This decompressive surgery gave the patient relief of her sciatic pain although back pain persisted.

### **DISCUSSION**

As we teach, it is our responsibility to follow each case through to its most successful clinical outcome. This is an example of meeting that obligation.

### **NOTE**

I plan to present this case in the next interdisciplinary conference October 9 & 10, 2010, in Fort Wayne, Indiana at Lutheran Hospital.

## IMAGING

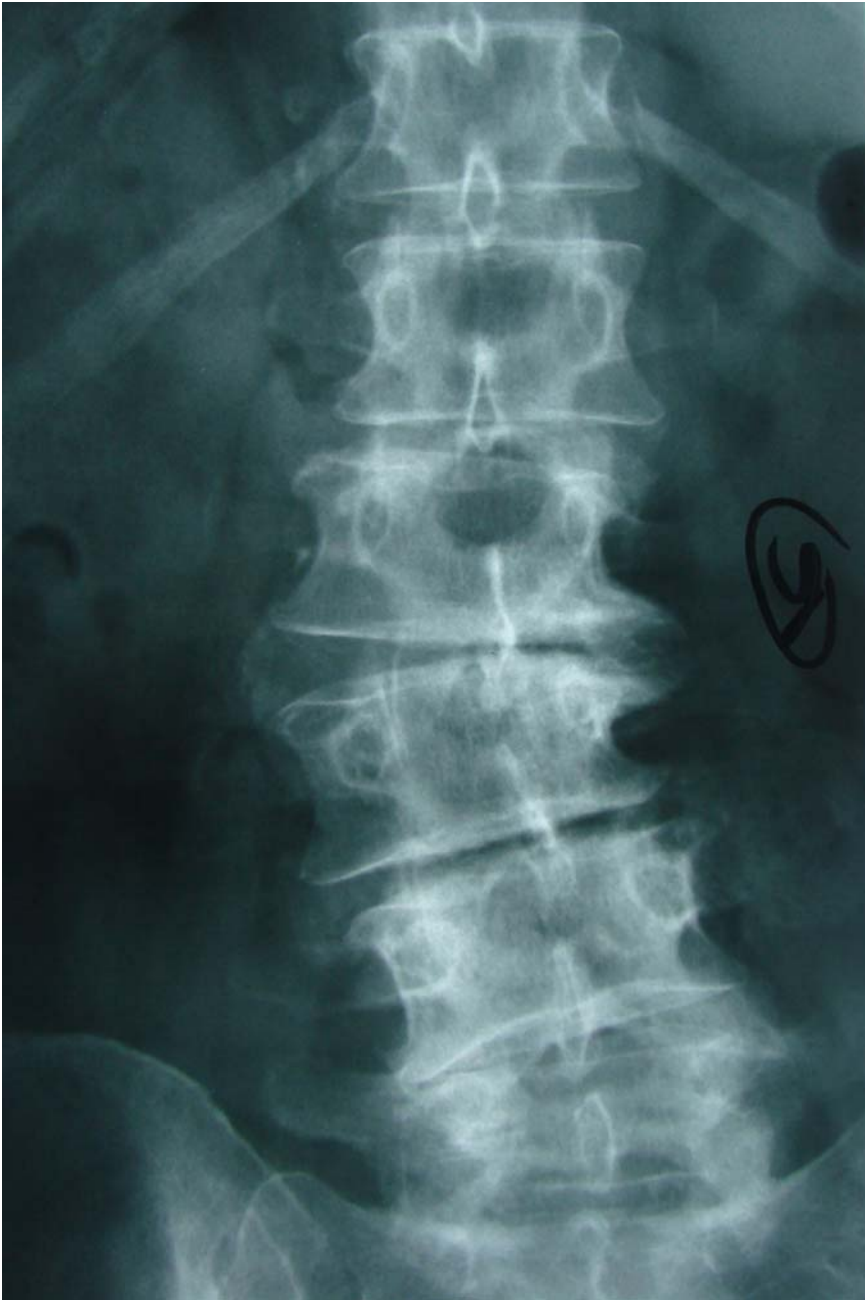

Figure 1 is the anteroposterior plain x-ray study showing the scoliosis and discogenic changes responsible for the spinal stenosis and resultant sciatic radiculopathy shown on MRI below

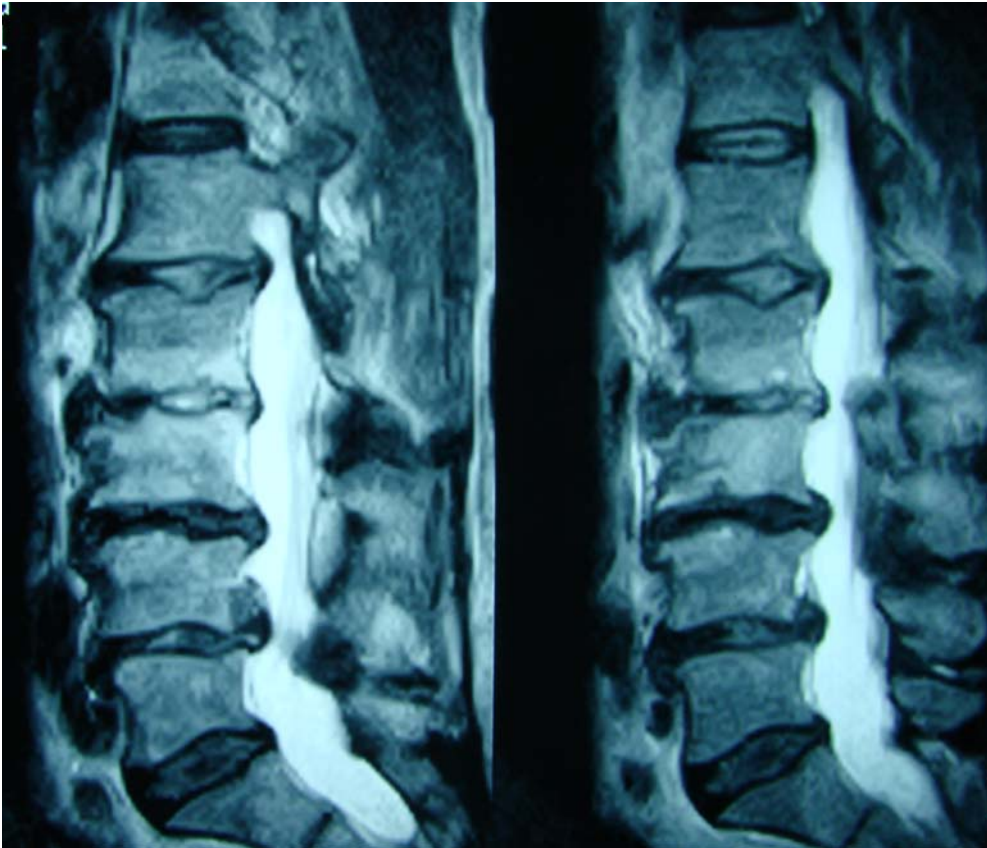


Figure 2 is the sagittal MRI view of the lumbar spine and shows the disc degeneration and posterior multilevel disc protrusion, discogenic spondylosis, and ligamentum flavum hypertrophy causing multilevel spinal stenosis

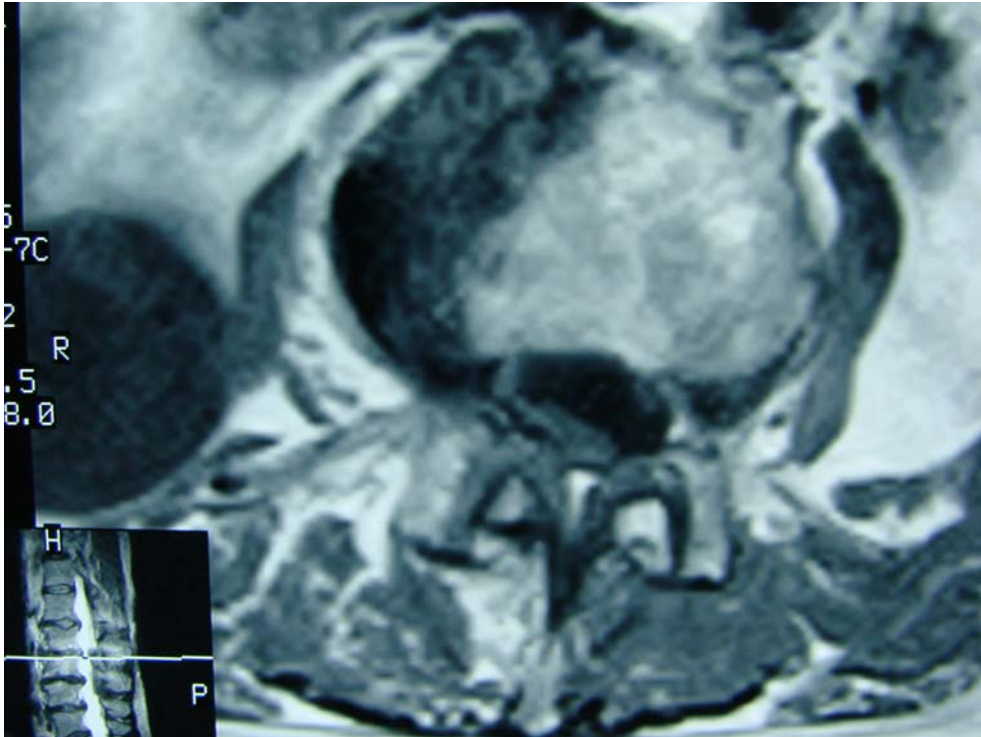


Figure 3 is the axial MRI image at the L2-L3 level showing the deformed spinal canal due to the scoliosis and the advanced discogenic changes resulting in posterior and lateral endplate hypertrophy and ligamentum flavum hypertrophy with facet arthrosis resulting in marked spinal and osseoligamentous canal stenosis.

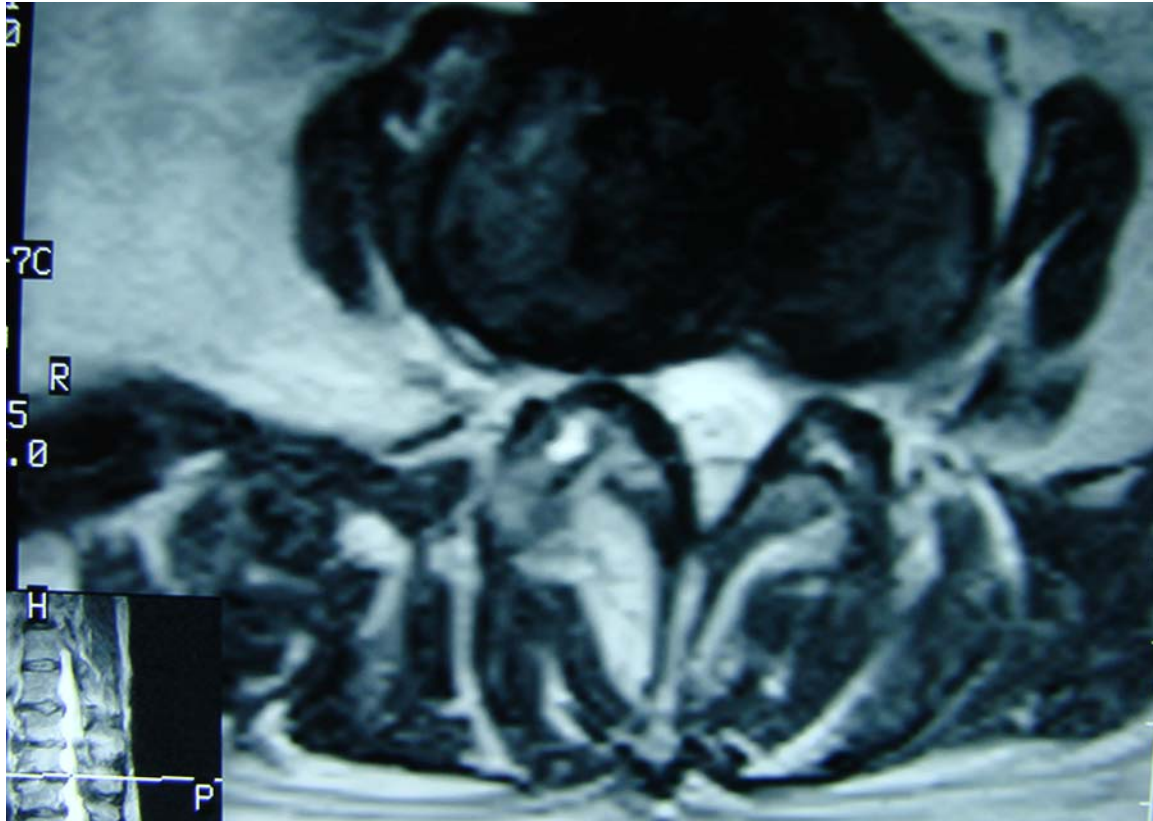


Figure 4 is an axial MRI image at the L3-L4 level showing endplate hypertrophy causing bilateral osseoligamentous foraminal stenosis with facet arthrosis and ligamentum flavum hypertrophy resulting in posterior and lateral stenosis of the vertebral and osseoligamentous canals. Hyperintensity within the bilateral facet joints and ligamentum flavi are noted suggesting synovial cyst change.



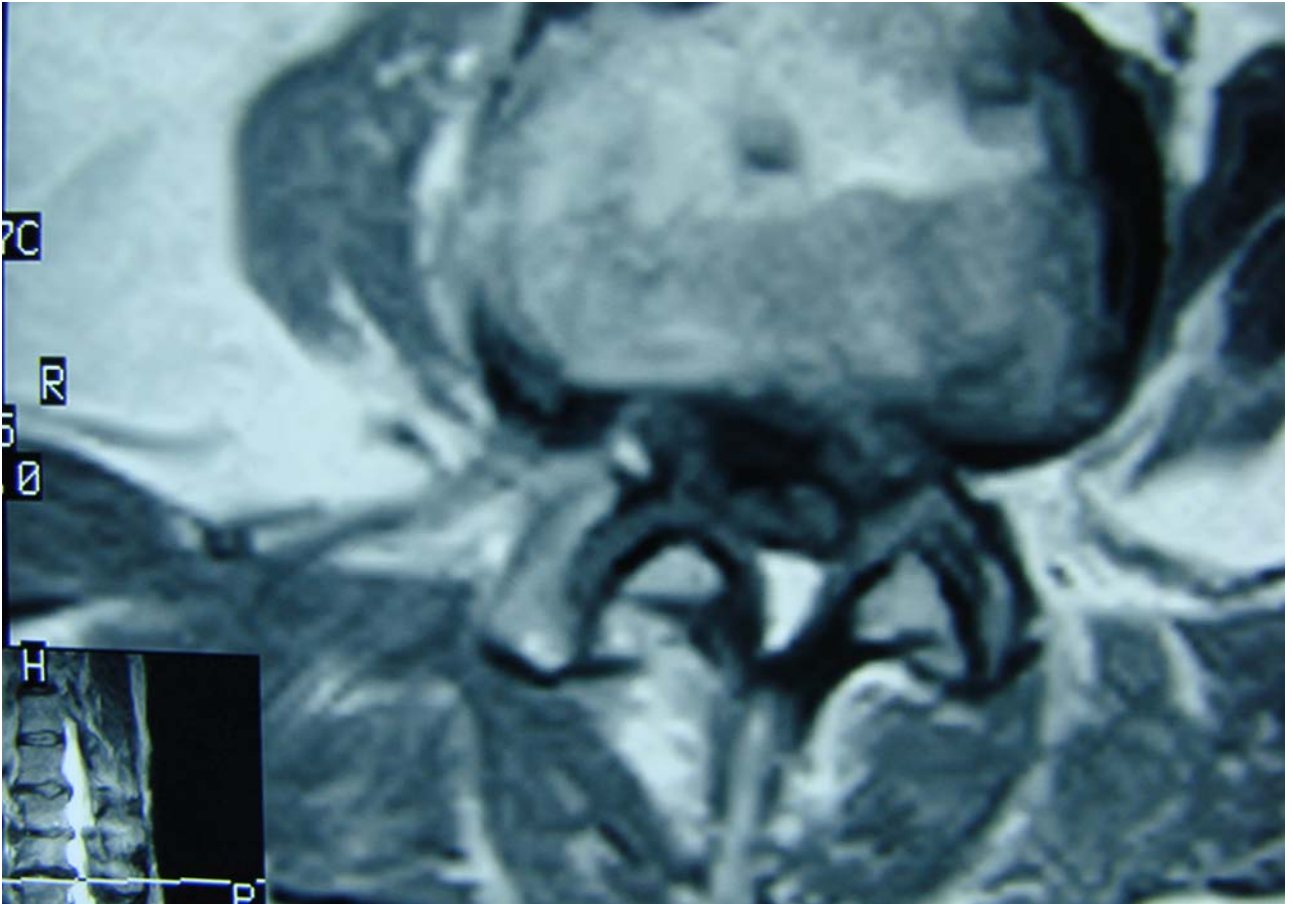


Figure 5 is another axial L3-L4 image showing endplate hypertrophy bilaterally at the posterolateral vertebral body causing bilateral foraminal stenosis. The facet arthrosis and ligamentum flavum hypertrophy contribute to the stenosis by narrowing the posterior vertebral and foraminal areas.

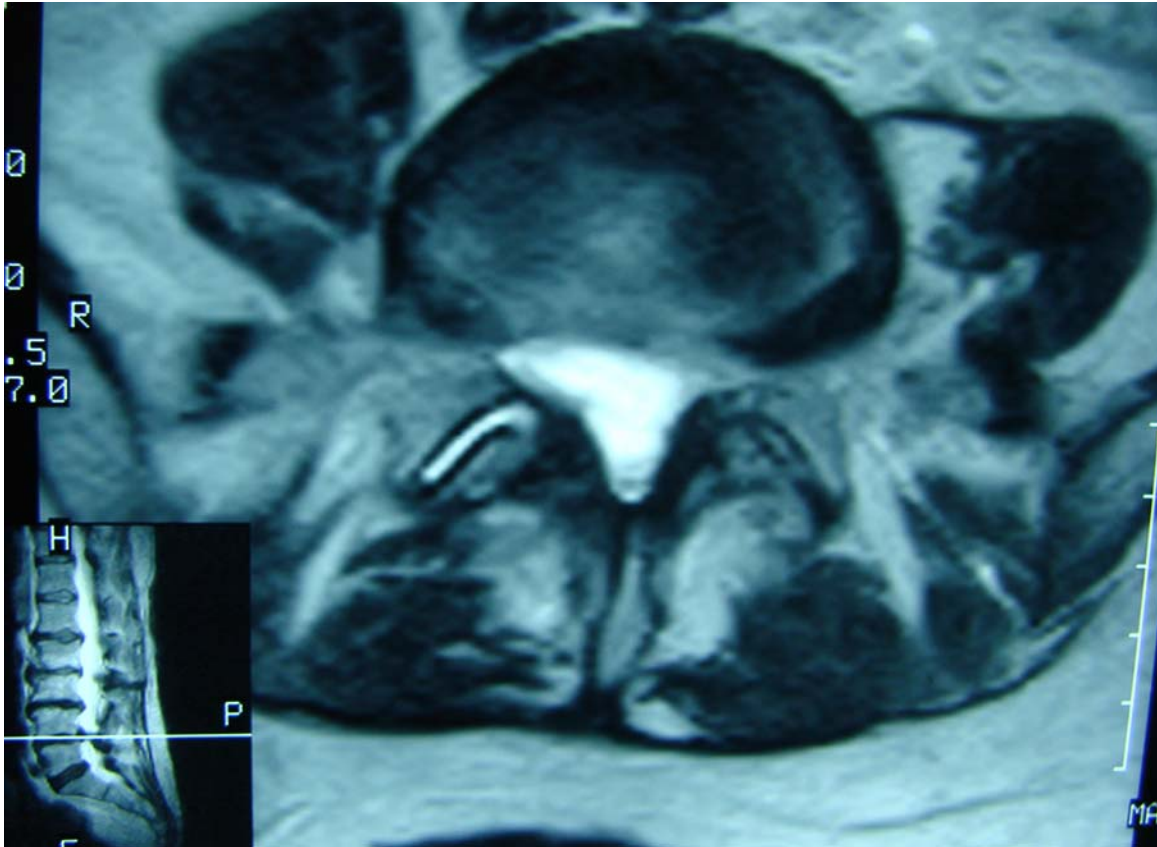


Figure 6 is the L4-L5 axial image showing the rotatory effects of the spinal vertebra on the foraminal canal size as well as the endplate hypertrophy bilaterally, most marked on the left side, resulting in foraminal osseoligamentous canal stenosis. Facet arthrosis is noted on the left side with ligamentum flavum thickening.

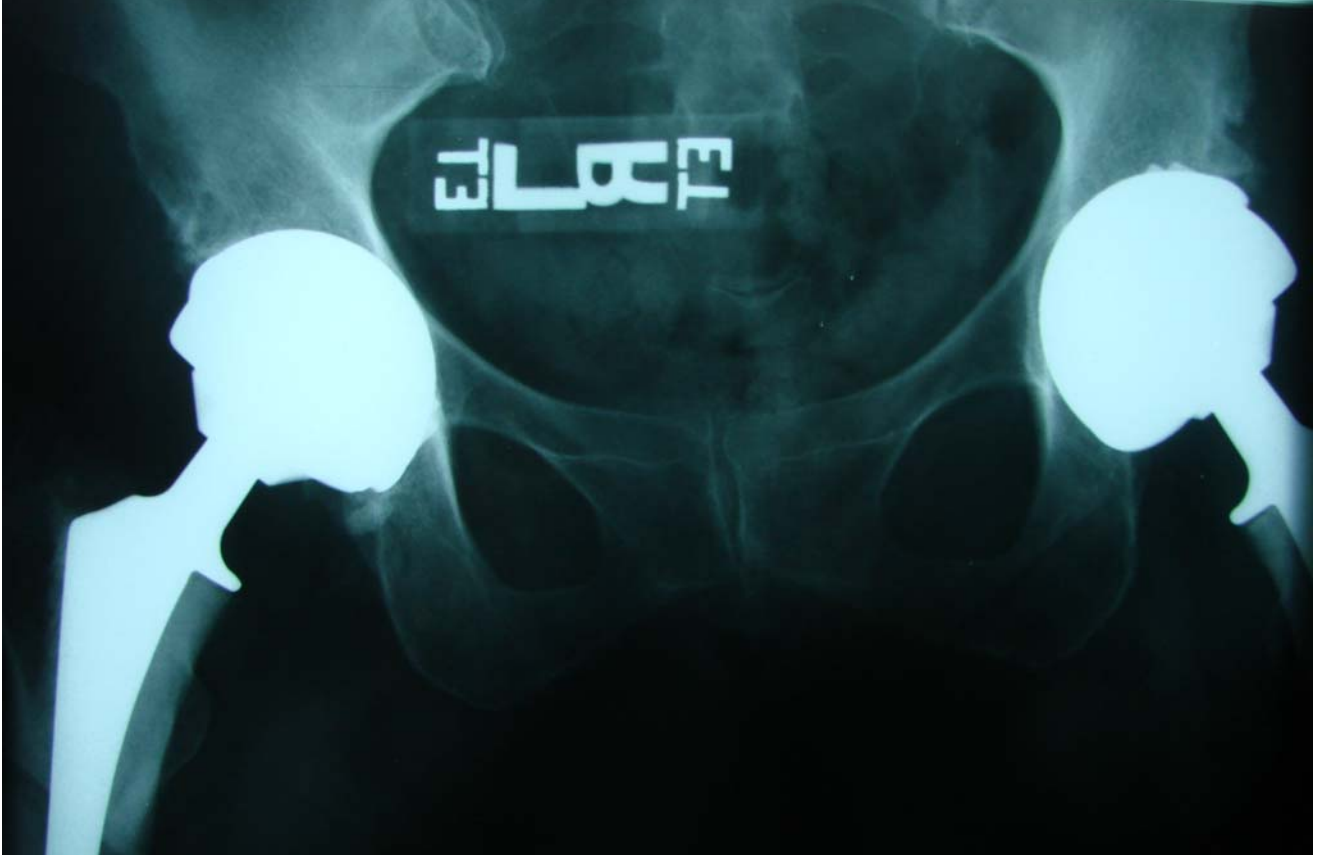

Figure 7 reveals the bilateral hip replacements preceding the onset of the stenotic symptoms. This did restrict the distraction force that could be applied to this spine when attempting to relieve the stenosis lower extremity generated pain.



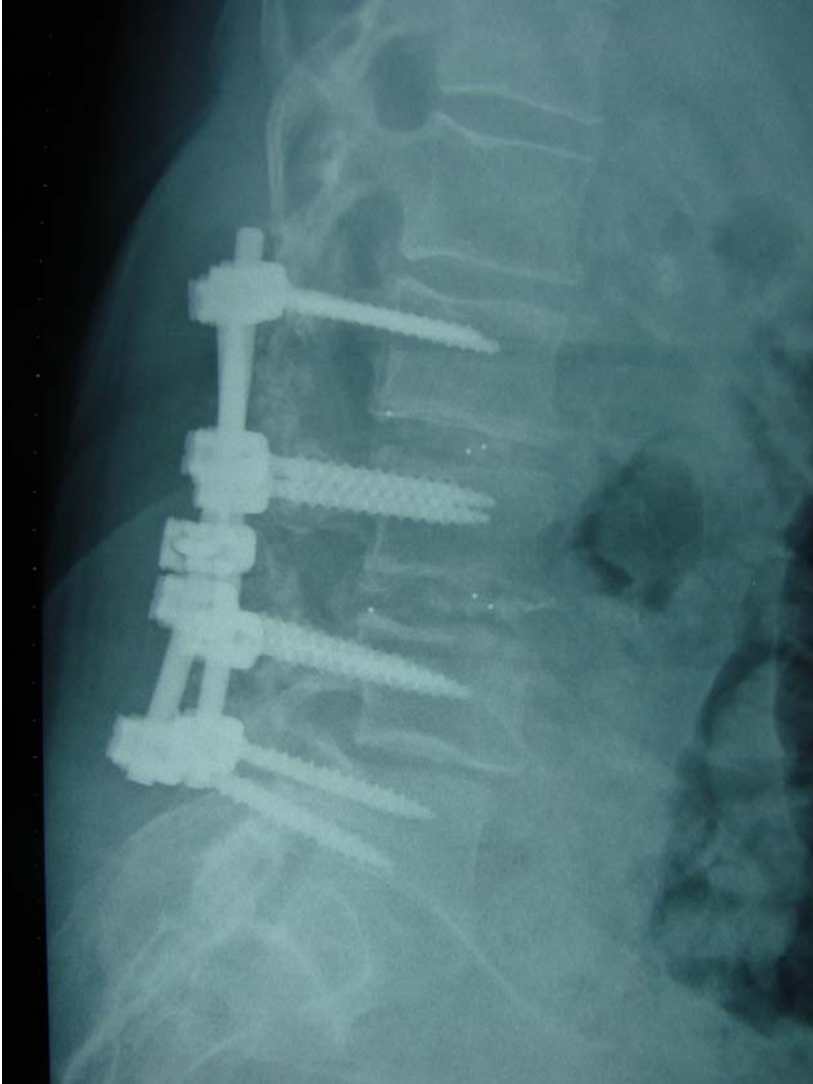


Figure 8 is the plain sagittal xray showing the increased disc space height and decompression laminectomy with spinal bolt and rod fusion as well as intertransverse bone fusion. The restoration of disc height is remarkable.

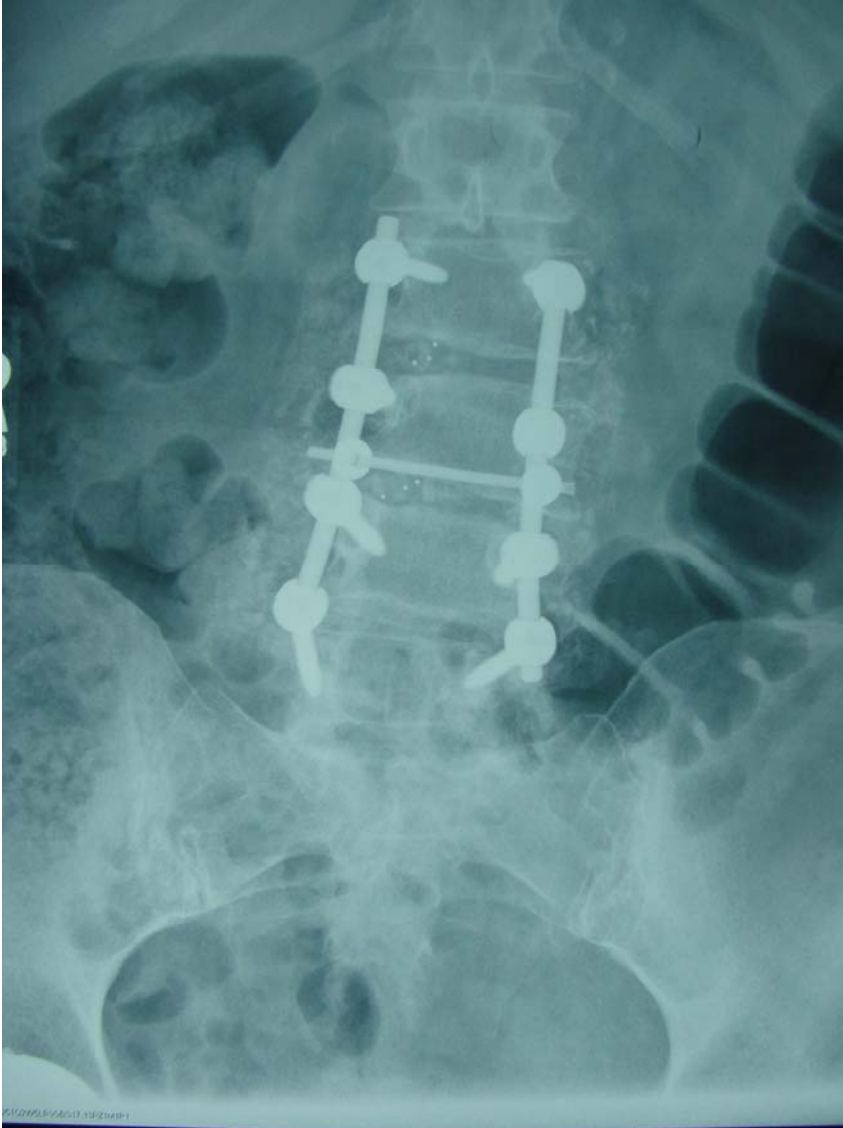


Figure 9 shows the rod and bolt fusion with the intertransverse process bone fusion. Note the decompressive laminectomies at the L2-3, L3-4, and L4-5 levels and straightening of the scoliosis.